
PATIENT PRESENTING CLINICAL SIGNS

Ernie Gorgenyi History: Hematemesis.

SPECIES Physical Examination: N/A.

Canine Urinalysis: N/A.

BREED CBC: Normal.

Weimaraner Serum Biochemistry: Normal.

Radiographic Findings: Possible left renomegaly.

SEX

MN

Age

10 years

WEIGHT

27.1 kg

INTERPRETED BY

Remo Lobetti, BVSc,
MMedVet (Med), PhD, Dipl.
ECVIM

ULTRASONOGRAPHIC EXAMINATION OF THE ABDOMEN
Urinary System

Small urinary bladder with a normal thickness and appearance of the wall. Normal anechoic urine with no sediment or uroliths evident.

Normal trigone area, proximal urethra, and iliac blood vessels.

Normal iliac lymph nodes. Ureters not visualized.

Normal renal size (left 6 cm, right 6.5 cm), echogenic appearance, cortico-medullary differentiation, pelvis, and capsule.

Reproductive System

Small hypoechoic prostate.

IMAGING PERFORMED BY

Dave Stasiuk RDMS, RDCS

Adrenal Glands

Normal position, echogenic appearance, shape, and size. Left 0.6 cm.

HOSPITAL NAME

Glamorgan Animal Clinic

Spleen

Normal size and echogenic appearance. Smooth homogenous parenchyma, regular curvilinear capsule, and normal vasculature. No evidence of inflammatory, neoplastic, infarction, or infiltrative changes noted.

REFERRING VET

Dr Kevin MacAulay

Liver

Normal size, echogenic appearance, portal markings, and regular curvilinear capsule. No nodules or masses evident. Full gall bladder containing normal anechoic bile. Normal thickness and echogenic appearance of the gall bladder wall. Normal bile duct.

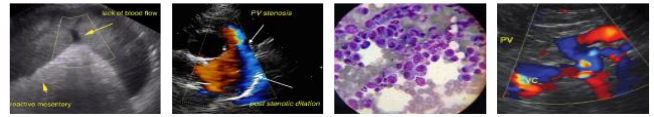
INVOICE

303698

Gastrointestinal
DATE

12/23/22

Normal appearance of the stomach, duodenum, small intestine, ileo-cecal junction, and colon with no loss of layering, normal wall thickness and peristaltic activity, and no distension of the lumen. Ingesta with in the stomach and small intestine.



PATIENT *Pancreas*

Ernie Gorgenyi Normal size and echogenic appearance. Regular capsule. Normal echogenic appearance of the mesentery and fat surrounding the pancreas.

SPECIES *Free Abdomen*

Canine No mesenteric lymphadenomegaly
No ascites.

BREED

Weimaraner

ULTRASONOGRAPHIC FINDINGS

SEX Primary Findings:

- None.

MN

Age Secondary Findings:

- None.

10 years

WEIGHT

27.1 kg

INTERPRETATION OF THE FINDINGS & FURTHER RECOMMENDATIONS

Normal ultrasound examination of the abdomen.

INTERPRETED BY

Remo Lobetti, BVSc,
MMedVet (Med), PhD, Dipl.
ECVIM

The information and recommendations provided are based on the images presented by the referring veterinarian. No evaluation can be communicated regarding pathology that was not visible in the image/video clips provided.

IMAGING PERFORMED BY

Dave Stasiuk RDMS, RDCS

Thank you for this referral. If the clinical or image interpretation does not parallel your findings or if I can be of any further assistance, please contact me.

HOSPITAL NAME

Glamorgan Animal Clinic

Remo Lobetti, BVSc, MMedVet (Med), PhD, Dipl. ECVIM (Internal Medicine)
rlobetti@mweb.co.za

REFERRING VET

Dr Kevin MacAulay

INVOICE

303698

DATE

12/23/22